

Anti-arthritic Effects of Bark Extracts of *Holoptelea integrifolia* (Roxb). Planch in a Chronic Inflammatory Model

N. Shinu Balima^{1*}, P. Sriram², S. Sri Nandhini³ and Shriharsh R. Bijargi⁴

¹PhD Scholar, ²Professor and Head, Department of Pharmacology and Toxicology, Madras Veterinary College, Tamil Nadu Veterinary and Animal Sciences University

³Post-doctoral fellow, Oklahoma State University, USA

⁴Investigator, Preclinical Safety, Novartis, India

*Corresponding Author E-mail: drshinuluther@gmail.com

Received: 12.02.2020 | Revised: 23.03.2020 | Accepted: 3.04.2020

ABSTRACT

Rheumatoid arthritis is an autoimmune disorder characterized by synovial proliferation, inflammation, cartilage destruction and deformity of the joints and a major cause of disability. A wide range of drugs are being used in the treatment, which causes severe side effects in the long run. Hence the current study was undertaken to explore the anti-arthritic effect of aqueous and ethanolic bark extracts of *Holoptelea integrifolia*, at different doses (200 mg/kg and 400 mg/kg), in comparison with the standard drug Diclofenac sodium (1mg/Kg) in adjuvant induced arthritic model in rats. The treatment was assessed by measuring the paw volume and by using various hematological parameters like haemoglobin, total red blood cell count, white blood cell count and C reactive protein. All the extracts of *Holoptelea integrifolia* reduced severity FCA induced arthritis extract, with significant effect at 400 mg /Kg.

Keywords: Rheumatoid arthritis, adjuvant induced arthritis, *Holoptelea integrifolia*, paw volume

INTRODUCTION

Rheumatoid arthritis (RA) belongs to a group of disorders broadly termed as rheumatic diseases. Articular involvement is manifested clinically by joint pain, stiffness, limitation of motion and signs of inflammation (Rindfleisch & Muller, 2005). Arthritis being a chronic inflammatory condition, its treatment takes a long course, which can cause serious side effects to the health of the individual. Novel drugs from alternate system of medicine could

provide a suitable replacement, being economical, locally available and devoid of side effects.

Holoptelea integrifolia (Roxb) also called as Indian elm is a very popular traditional plant in India. It is used traditionally for the treatment of inflammation, gastritis, dyspepsia, colic, intestinal worms, vomiting, wound healing, leprosy, diabetes, hemorrhoids, dysmenorrhoea and rheumatism (Sharma & Singh, 2012).

Cite this article: Balima, N.S., Sriram, P., Nandhini, S.S., & Bijargi, S.R. (2020). Anti-arthritic Effects of Bark Extracts of *Holoptelea integrifolia* (Roxb). Planch in a Chronic Inflammatory Model, *Ind. J. Pure App. Biosci.* 8(4), 103-108. doi: <http://dx.doi.org/10.18782/2582-2845.7955>

The bark extracts were used topically by local healers for inflammation of the knee joints. However, to our knowledge, there are no published scientific studies on the anti-arthritic activities of bark of *Holoptelea integrifolia*. Therefore, the objective of this study is to examine the anti-arthritic potential of aqueous and alcoholic bark extracts after oral administration of *Holoptelea integrifolia*

MATERIALS AND METHODS

Plant Material

Bark of *Holoptelea integrifolia* was obtained from local dealers in traditional medicine, Nagercoil, Tamil Nadu. Air dried bark is blended to a fine powder and extracted by maceration. Both aqueous and alcoholic extracts were prepared by mixing one part of the powdered material with four parts of the solvent. The filtrate is dried using a rotary evaporator. The yield was about 3.7 and 1 percent w/w for aqueous and ethanolic extracts respectively

Phytochemical Analysis

Qualitative tests were carried out for the presence of active phytochemicals in the respective extracts. The aqueous and ethanolic extracts of the plant were subjected to GC-MS analysis in order to identify the active principles present in the plant.

Experimental Animal

Wistar rats of either sex, weighing approximately 150-200g, procured from the Laboratory Animal Medicine Unit, Directorate Centre for Animal Health Studies, Madhavaram, Chennai – 51, were used in this study. The study was carried out after approval from Institutional Animal Ethics Committee (IAEC). The rats were housed in solid bottomed polypropylene cages. The room was maintained in standard conditions of temperature at $25 \pm 2^{\circ}$ C, relative humidity at 50 – 70% and 12:12 hr dark and light cycle. The rats were fed with standard pellet feed obtained (Provimi Animal Nutrition India Pvt. Ltd., Bangalore) and water was provided *adlibitum* throughout the study period.

Experimental design

Animals are divided into seven groups with ten animals in each group. The rats were acclimatized for a period of seven days before the start of the experiment. Group I -untreated control, Group II- Arthritic control, Group III- Arthritis + Diclofenac (1 mg/kg), Group IV- Arthritis + *Holoptelea integrifolia* (aqueous extract - 200mg/kg), Group V- Arthritis + *Holoptelea integrifolia* (aqueous extract - 400mg/kg), Group VI- Arthritis + *Holoptelea integrifolia* (ethanolic extract - 200mg/kg), group VII- Arthritis + *Holoptelea integrifolia* (ethanolic extract - 400mg/kg)

Induction of adjuvant arthritis in rats

Freund's complete adjuvant (Chondrex, Inc. USA) was suspended in mineral oil with a final concentration of 10 mg/ ml. Arthritis was induced by injecting about 0.05 ml of Freund's complete adjuvant below the plantar aponeurosis of the right hind paw of the rats (Newbould, 1963, Whitehouse, 1998) on day 8 after acclimatization for a period of seven days. Paraffin oil (0.05ml) oil was injected into the right hind paw of another group of rats which served as untreated control.

Treatment of animals

All the animals in groups III, IV, V, VI and VII were treated continuously from day 10 after induction of AIA for a period of 20 days by oral dosing. Diclofenac (Himedia laboratories Pvt). Ltd., Mumbai and HI aqueous extract were dissolved in distilled water, whereas ethanolic extract was administered as a 0.1% solution(prepared in dimethyl sulfoxide (DMSO) (upto 10% of 10 ml solution). No treatment was given to the rats in untreated control and arthritic control.

Measurement of paw swelling

The changes in the oedema of right hind paw was measured on 8th, 12th, 16th, 21st, 26th, 31st and 36th day using digital plethysmometer (Panlab digital plethysmometer). The initial level of the fluid and final level after dipping the foot is noted. The difference between the initial and final volumes indicated the oedema volume. Calculation of percent inhibition of paw volume $\left[\frac{V_c - V_t}{V_c} \right] \times 100$, where, V_c -

oedema volume of arthritic control group and *Vt*- oedema volume of treatment group.

Haematological and Biochemical assays

Whole blood was collected from animals on 36th day and was used to assess haematological parameters such as Packed Cell Volume (PCV), Haemoglobin, RBC, WBC, platelets count. C-Reactive Protein levels in serum was estimated quantitatively which is a turbidimetric immunoassay.

Statistical analysis

The data were statistically analysed by using non parametric Duncan's one way analysis of variance.

RESULTS

Phytochemical Analysis

Phytochemistry of the plant had revealed the presence of several phytoconstituents such as tannins, saponins, flavonoids, alkaloids, quinones, terpenoids, phenols, coumarins and proteins in aqueous extracts whereas tannins, saponins, proteins were absent in ethanolic extract. The chromatogram obtained from GC-MS analysis of the aqueous and ethanolic extracts indicate the presence of at-least eleven peaks for aqueous and ten peaks for ethanolic extract suggesting the presence of multiple phytoconstituents. Analysis of the chromatogram has shown the presence of an active principle, Friedelan- 3- one in the ethanolic extract.

Changes in paw volume

In arthritic control (Group II) rats, swelling and redness developed over 24 hour period in the right hind paw injected with adjuvant and reached maximum intensity after 9-14 days from the day of induction. Paw volume of all the rats of both control and treatment groups were measured on days 8, 12, 16, 21, 26, 31, 36 using digital plethysmometer. The paw volumes of the arthritic control group kept increasing gradually till day 31 and then decreased slightly whereas paw volumes of all treatment groups (Groups IV to VII) has shown a considerable reduction in paw volume (Fig. 1) compared to diclofenac group (Group III). (Table 1)

Haematological and Biochemical changes

A significant decrease in haemoglobin and total erythrocyte was seen in arthritic control group. But those changes were reversed by the treatment and no significant changes were noticed among the treatment groups in comparison with the standard drug group. An increase in TLC and C reactive protein was seen in arthritic control group. The increases in WBC count, serum C-reactive protein level were significantly suppressed in the extract-administered arthritic group. (Table 2).

DISCUSSION

Freund's complete adjuvant (FCA)-induced arthritis is a model that have been extensively used to study the pathogenesis of RA for therapeutics testing. Adjuvant induced arthritis is thought to occur through cell mediated auto immunity by structural mimicry between mycobacteria and cartilage proteoglycans in rats (Van Eden, Holoshitz, Nevo, Frenkel, Klajman, & Cohen, 1985). In AIA, heat killed mycobacterium tuberculosis cells do not degrade but remain in the synovium as perpetual antigens (Arend, 1997) and can initiate an inflammatory cascade mimicking RA.

Paw swelling is one of the major factors in assessing the degree of inflammation and curative efficacy of drugs. On treatment with extracts of *Holooptelea integrifolia* significant reduction in paw swelling has been observed. This reduced edema formation may be due to its inhibitory action on prostaglandin synthesis (Williams, 1979). Triterpenoids are able to significantly reduce the paw swelling in AIA model (Agarwal & Rangari, 2003) and the reduction in paw swelling in this study may be due to the presence of terpenoids which possess anti-inflammatory action.

Anaemia is commonly noted in patients with chronic arthritis which may be due depression of bone marrow due to formation of immune complexes The results of the study concur with the findings of Malik, Manvi1, Nanjware, Dwivedi, Purohit, & Chouhan (2010). Mowat (1971) suggested that during arthritis, iron is not released as well as

incorporated in haemoglobin. The reversal of these effects to normalcy after treatment may be due to the erythropoietic effect of the plant.

An elevated TLC was seen in arthritic control which shows that inflammation persists. The reversal of these effects to normalcy after treatment may be due to the erythropoietic effect as well the anti-inflammatory effect of the plant.

An indicator of infectious and inflammatory diseases the WBC count was increased in arthritic rats. The migration of leukocytes to the inflamed area was significantly suppressed by this plant extract, as indicated by the significant decrease in the WBC count which shows its anti-inflammatory effect.

C-reactive protein is a member of the class of acute phase reactants - its levels rise dramatically during inflammatory processes. C-Reactive protein is elevated in response to stress or inflammation that occurs after infection, injury, surgery and tissue damage (Blake & Swift, 2004). Elevated C-reactive protein in arthritic suggests an active inflammation. The concentration of C-reactive protein was found to be significantly reduced in the plant-treated as well as the diclofenac-treated groups.

Taken together, our results strongly support the antiarthritic potential of the plant

and its use in traditional medicine. The anti-inflammatory activities could be attributed to the presence of several phytoconstituent alkaloids (Sais, Vidaller, Jucgla, Gallardo, & Peyri, 1995) and terpenoid compounds (Shimizu & Tomoo, 1994, Nsonde Ntandou, Banzouzi, Mbatchi, Elion-Itou, Etou-Ossibi, Ramos, Benoit-Vical, Abena, & Ouamba, 2010). Antioxidant properties of Flavonoids (Lee, Son, Chang, Kang, Kim, 1997, Middleton, Kandasamy, & Theoharides, 2000, Sadhu, Okuyama, Fujimoto, & Ishibashi, 2003, Kim, Son, Chang, & Kang, 2004, Raoa, Fang & Tzen, 2005) and phenolic compounds (Ahmed, Wang, Lalonde, Goldberg, & Haqqi 2003). Friedelin, a triterpenoid is found to possess significant anti-inflammatory action (Antonisamy, Duraipandiyar & Ignacimuthu, 2011).

Among the extracts, both aqueous and ethanolic are equally efficacious in reducing the paw swelling. However the parameters that determine the progression of arthritis suggest that ethanolic extract at the dose of 400 mg /kg was able to produce significant effects This may be due to the difference in the concentration of phytoconstituents in the extracts. A better result was seen at the higher dose of 400 mg / kg.

Table 1: Effect of *Holoptelea integrifolia* on paw volume (ml) changes in AIA

Groups	Day 8	Day 12	Day 16	Day 21	Day 26	Day 31	Day 36
I- Sham control	2.60 ^a ± 0.25	2.71 ^a ± 0.25	2.79 ^a ± 0.27	2.77 ^a ± 0.28	2.74 ^a ± 0.29	2.71 ^a ± 0.29	2.69 ^a ± 0.29
II- Arthritic control	2.61 ^a ± 0.26	4.99 ^c ± 0.09	4.78 ^b ± 0.1	5.41 ^c ± 0.13	5.71 ^d ± 0.14	6.20 ^d ± 0.05	6.08 ^e ± 0.06
III - A+ Diclofenac 1mg/kg	2.91 ^{ab} ± 0.08	5.05 ^c ± 0.39	4.69 ^b ± 0.32	4.92 ^{bc} ± 0.29	4.40 ^b ± 0.07	3.95 ^b ± 0.13	3.55 ^b ± 0.01
IV- A+ HI aq. 200mg/kg	3.00 ^{ab} ± 0.43	5.32 ^c ± 0.22	4.67 ^b ± 0.37	5.21 ^{bc} ± 0.30	5.06 ^c ± 0.37	4.99 ^c ± 0.38	4.95 ^{cd} ± 0.39
V -A+ HI Eth. 200 mg/kg	3.45 ^b ± 0.11	5.08 ^c ± 0.05	4.74 ^b ± 0.11	5.33 ^c ± 0.07	5.24 ^{cd} ± 0.07	5.16 ^c ± 0.11	5.05 ^d ± 0.10
VI -A+ HI aq. 400 mg/kg	2.33 ^a ± 0.11	4.28 ^b ± 0.20	4.44 ^b ± 0.13	4.54 ^b ± 0.06	4.22 ^b ± 0.01	4.05 ^b ± 0.10	3.79 ^b ± 0.07
VII- A+ HI Eth. 400 mg/kg	2.91 ^{ab} ± 0.08	5.17 ^c ± 0.17	4.76 ^b ± 0.28	5.11 ^{bc} ± 0.22	4.69 ^{bc} ± 0.19	4.59 ^{bc} ± 0.17	4.40 ^c ± 0.02

Table 2: Effect of *Holooptelea integrifolia* on haematological and biochemical parameters on day 36

	Haemoglobin (gm/dl)	PCV %	TEC (millions/mm ³)	TLC (Cells/mm ³)	CRP (mg/dl)
I Sham control	15.02 ^c ±0.33	39.17 ^a ±0.34	6.72 ^a ±0.38	6866.67 ^a ±202.76	-
II Arthritic control	10.98 ^a ±0.49	39.08 ^a ±1.34	6.11 ^a ±0.26	9550.00 ^b ±624.37	14.13 ^a ±0.20
III -A+ Diclofenac 1mg/kg	12.83 ^b ±0.32	37.13 ^a ±0.69	6.86 ^{ab} ±0.14	6990.00 ^a ±477.59	2.40 ^d ±0.26
IV -A+ HI aq. 200mg/kg	14.73 ^c ±0.27	41.33 ^{ab} ±1.89	7.70 ^c ±0.15	7683.33 ^a ±461.46	6.27 ^b ±0.19
V-A+ HI Eth. 200 mg/kg	15.58 ^c ±0.23	44.30 ^b ±0.35	7.79 ^c ±0.42	7083.33 ^a ±676.96	6.43 ^b ±0.29
VI-A+ HI aq. 400 mg/kg	15.45 ^c ±0.25	43.53 ^b ±0.95	7.55 ^{bc} ±0.10	7083.33 ^a ±1040.33	6.00 ^b ±0.32
VII-A+ HI Eth. 400 mg/kg	15.03 ^c ±0.25	41.33 ^{ab} ±2.32	7.59 ^{bc} ±0.16	5750.00 ^a ±579.51	5.20 ^c ±0.06

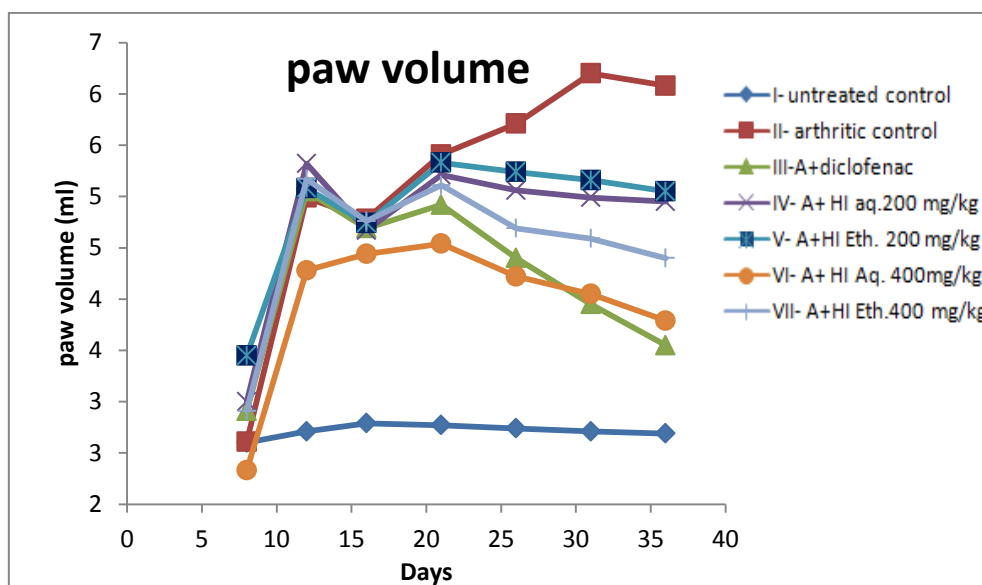


Figure 1: Changes in paw volume

CONCLUSION

Hence *Holooptelea integrifolia* could be considered as a potential for the treatment of RA. However identification of the active principle that is exactly responsible for the anti-arthritis activity and the elucidation of its mechanism of action will help validate its utility in the therapy of arthritis.

Acknowledgement

The first author thanks Tamil Nadu Veterinary and Animal Sciences University (TANUVAS) for providing necessary facilities to carry out and complete her MVSc thesis research work.

REFERENCES

Agarwal, R.B., & Rangari, V.D. (2003). Anti-inflammatory and anti-arthritis activities of Lupeol and 19 α -H Lupeol

isolated from *Strobilanthes callosus* and *Strobilanthes Ixioccephala* roots. *Indian J. pharmacol.* 35, 384-387.

Ahmed, S., Wang, N., Lalonde, M., Goldberg, V.M., & Haqqi, T.M. (2003). Green tea polyphenol Epigallocatechin-3-gallate (EGCG) differentially inhibits interleukin-1 β -induced expression of Matrix metalloproteinase-1 and -13 in human chondrocytes. *J. Pharmacol. Exp. Therapeut.* 308, 767-773,

Antonisamy, P., Duraipandiyar, V., & Ignacimuthu, S. (2011). Anti-inflammatory, analgesic and antipyretic effects of friedelin isolated from *Azima tetracantha* Lam. in mouse and rat models, *J. Pharmacol. Pharmacol.* 63, 1070-1077.

- Arend, W. P. (1997). *Arthritis & Rheumatism* in 1997. *Arthritis Rheum.* 82, 595-597.
- Blake, S.M., & Swift, B.A. (2004). What next for rheumatoid arthritis therapy? *Curr. Opin. Pharmacol.* 4, 276-280
- Kim, H.P., Son, K.H., Chang, H.W., & Kang, S.S. (2004). Anti-inflammatory Plant Flavonoids and Cellular Action Mechanisms. *J.Pharmacol. Sci.* 96, 229 – 245.
- Lee, S. J., Son, K.H, Chang, H. W., Kang, S. S., & Kim, H.P. (1997). Inhibition of arachidonate release from rat peritoneal macrophages by bioflavonoids. *Arch. Pharm. Res.* 20, 533–538.
- Malik, J.K., Manvi, F.V., Nanjware, B.R., Dwivedi, D.K., Purohit, P., & Chouhan, S. (2010). Anti-arthritic activity of leaves of *Gymnema sylvestre* R.Br. leaves in rats. *Der pharmacia lettre.* 1, 1336-341
- Middleton, E. Jr., kandaswami, C., & Theoharides, T.C. (2000). The Effects of Plant Flavonoids on Mammalian Cells: Implications for Inflammation, Heart Disease, and Cancer. *Pharmacol. Rev.* 52, 673–751.
- Mowat, G. (1971) Haematological abnormalities in rheumatoid arthritis. *Semin Arthritis Rheum.* 1, 195-9.
- Newbould, B.B. (1963). Chemotherapy of arthritis induced in rats by mycobacterial adjuvant. *Br. J. Pharmacol. Chemother.*, 21, 127–136.
- Nsonde Ntandou, G.F., Banzouzi, J.T., Mbatchi, B., Elion-Itou, R.D., Etou-Ossibi, A.W., Ramos, S., Benoit-Vical, F., Abena, A.A. & Ouamba, J.M. (2010). Analgesic and anti-inflammatory effects of *Cassia siamea* Lam. stem bark extracts. *J. Ethnopharmacol.* 127(1), 108-111.
- Raoa, Y. R., Fang, S., & Tzen, Y. (2005). Anti-inflammatory activities of flavonoids isolated from *Caesalpinia pulcherrima*. *J. Ethnopharmacol.*, 100, 249-253.
- Rindfleisch, J. A., & Muller, D. (2005). Diagnosis and management of Rheumatoid arthritis. *Am. Fam. Physician.*, 7, 1037-1049.
- Sadhu, S. K., Okuyama, E., Fujimoto, H., & Ishibashi, M. (2003). Separation of *Leucas aspera*, a medicinal plant of Bangladesh, guided by prostaglandin inhibitory and antioxidant activities. *Chem. Pharmaceut. Bull.* 51, 595–598.
- Sais, G., Vidaller, A., Jucgla, A., Gallardo, E., & Peyri, J. (1995). Colchicine in the treatment of cutaneous leukocytoclastic vasculitis: results of a prospective, randomized controlled trial. *Arch. Dermatol.* 131, 1399-1402.
- Sharma, J., & V. Singh, V. (2012). *Holoptelea integrifolia*: an overview. *Europ. J. Appl. Sci.* 1, 42-46.
- Shimizu, M. & Tomoo, T., (1994). Anti-inflammatory constituents of topically applied crude drugs. Vs. Constituents and anti-inflammatory effect of Aoki, *Aucuba japonica*. *Thunb. Biol. Pharm. Bull.* 17(5), 665-667
- Van Eden, W., Holoshitz, J., Nevo, Z., Frenkel, A., Klajman, A., & Cohen, I.R., (1985). Arthritis induced by a T-lymphocyte clone that responds to Mycobacterium tuberculosis and to cartilage proteoglycans. *Proc. Natl. Acad. Sci. Unit. States. Am.* 82, 5117–5120
- Whitehouse, M. W., (1998). In: CRC handbook of Animal Models For the rheumatic Diseases (R. A. Greenwald and H. S. Diamonds, eds) CRC press, INC. Florida, USA.
- Williams, T. J. (1979). Prostaglandins E₂, Prostaglandin I₂ and vascular changes of inflammation. *Br. J. Pharamacol.* 65, 517-524.